

識別番号・報告回数		報告日		第一報入手日	新医薬品等の区分		総合機構処理欄	
一般的名称		新製凍結人血漿		2009. 5. 18	該当なし		使用上の注意記載状況・ その他参考事項等	
販売名(企業名)		新製凍結血漿「日赤」(日本赤十字社) 新製凍結血漿-LR「日赤」(日本赤十字社) 新製凍結血漿-LR「日赤」成分採血(日本赤十字社)		研究報告の公表状況		公表国		新鮮凍結血漿「日赤」 新鮮凍結血漿-LR「日赤」 新鮮凍結血漿-LR「日赤」成分採血 血液を介するウイルス、 細菌、原虫等の感染 vCJD等の伝播のリスク
研究報告の概要		<p>○B型肝炎の再燃 B型肝炎の再燃とは、非活動性B型肝炎またはB型肝炎が治癒した患者で、B型肝炎ウイルス(HBV)が急増することである。再燃は自然に起こる場合もあるが、一般的には臓器移植の免疫抑制療法によって引き起こされることが多い。再燃は、一過性で非顕在性となる場合もあるが、疾患増悪を引き起こし、重症化して急性肝不全に至ることもある。ほとんどは再燃例は自然に治癒するが、免疫抑制が長く続く場合慢性肝炎を発症し、進行性肝障害や肝硬変に至る場合もある。もともとよく報告されている再燃例は、リンパ腫または白血病の癌化学療法治療を受けている非活動性またはほとんど活動性のないB型肝炎を有するB型肝炎患者にHBsAg陽性患者にHBV DNAの検出が認められる。通常は化学療法時に血清HBV DNA値が上昇し、化学療法中止後に免疫再構築による疾患増悪およびHBV DNAの検出が認められる。特異なパターンとしては、臓器および骨髄移植後に再燃が起る。以上により、癌化学療法または移植を受けるHBsAg陽性患者に対してルーチンの予防が推奨されるが、重大な疑問が残る。どのような患者にHBsAg陽性患者に移植を受けるべきか、全員の治療を行うべきか、どの抗ウイルス剤を、どのくらいの期間使うべきか? B型肝炎が治癒したHBsAg陰性患者に予防を行うべきか? 今後の研究では、異なる患者集団を対象として、再燃の分子学的発症機序、および診断、治療、予防の最適な方法について、取り組む必要がある。</p>		Hoofnagle JH. Hepatology. 2009 [May;49(5 Suppl):S156-65.]		米国		
報告企業の意見		<p>日本赤十字社では、薬事法及び関連法令に従い輸血副作用・感染症情報を収集し、医薬品医療機器総合機構を通じて国に報告している。HBV感染に関する新たな知見等について今後も情報の収集に努める。</p>		今後の対応				③

Reactivation of Hepatitis B

Jay H. Hoofnagle

Reactivation of hepatitis B refers to the abrupt increase in hepatitis B virus (HBV) replication in a patient with inactive or resolved hepatitis B. Reactivation can occur spontaneously, but more typically is triggered by immunosuppressive therapy of cancer, autoimmune disease, or organ transplantation. Reactivation can be transient and clinically silent, but often causes a flare of disease that can be severe resulting in acute hepatic failure. Most instances of reactivation resolve spontaneously, but if immune suppression is continued, re-establishment of chronic hepatitis occurs which can lead to progressive liver injury and cirrhosis. The best-described instances of reactivation occur in hepatitis B surface antigen (HBsAg) carriers with inactive or minimally active disease who are given cancer chemotherapy for lymphoma or leukemia. Typically, serum HBV DNA rises during chemotherapy, followed by a disease flare and HBV DNA clearance with immune reconstitution after chemotherapy is stopped. Special forms of reactivation occur after solid organ and bone marrow transplantation in which chronic infection often results. Several randomized, placebo-controlled trials have shown that reactivation can be prevented by antiviral prophylaxis. Routine prophylaxis is therefore recommended for persons with HBsAg undergoing cancer chemotherapy or transplantation, but major questions remain. Which patients should be screened for HBsAg and should all be treated? Which antiviral should be used and for how long? Should persons with resolved hepatitis B without HBsAg receive prophylaxis? Future research should address the underlying molecular mechanisms of reactivation as well as its optimal means of diagnosis, treatment, and prevention in different patient populations. (HEPATOLOGY 2009; 49:S156-S165.)

Introduction

Reactivation of hepatitis B is a well-characterized syndrome marked by the abrupt reappearance or rise of hepatitis B virus (HBV) DNA in the serum of a patient with previously inactive or resolved HBV infection. Reactiva-

tion is also often, but not always, accompanied by reappearance of disease activity or a flare of hepatitis in previously minimal or inactive disease. Reactivation can be spontaneous, but is most commonly triggered by cancer chemotherapy, immune suppression, or alteration in immune function. Reactivation can lead to clinically apparent acute hepatitis, which can be severe and result in acute liver failure and death. Nevertheless, a large number of cases of reactivation are subclinical and resolve spontaneously, or result in persistent infection which may go undetected until advanced liver disease is present or the disease has been transmitted to sexual or family contacts.

The importance of reactivation of hepatitis B rests on its potential severity and the ease of its prevention with prophylactic oral antiviral therapy. In addition, reactivation reveals fundamental features of HBV and its ability to persist in a latent replicative form for prolonged periods despite other evidence of viral clearance. Importantly, the lack of recognition of reactivation and its complex virological and biological features often cause confusion and delayed recognition until it has already occurred and caused clinical consequences. Furthermore, reactivation can be misdiagnosed as superimposition of another form

Abbreviations: AASLD, American Association for the Study of Liver Diseases; anti-HBe, antibody to hepatitis B core antigen; anti-HBc, antibody to hepatitis B surface antigen; anti-HBe, antibody to hepatitis B e antigen; HBcAg, hepatitis B e antigen; HBsAg, hepatitis B surface antigen; HBV, hepatitis B virus; HIV, human immunodeficiency virus; TNF, tumor necrosis factor.

From the Division of Digestive Diseases and Nutrition, National Institute of Diabetes and Digestive and Kidney Diseases, National Institutes of Health (NIH), Bethesda, MD.

Received February 11, 2009; accepted February 23, 2009.

This work was supported in part by the Intramural Division of the National Institute of Diabetes and Digestive and Kidney Diseases, NIH.

Presentation at: National Institutes of Health Consensus Development Conference: "Management of Hepatitis B", held October 20-22, 2008, Natcher Auditorium, NIH Campus, Bethesda, MD.

Address reprint requests to: Jay H. Hoofnagle, M.D., Building 31, Room 9A27, 31 Center Drive, NIH, Bethesda, MD 20892. E-mail: Hoofnaglej@exrn.niddk.nih.gov; fax: 301-480-2376.

Copyright © 2009 by the American Association for the Study of Liver Diseases. Published online in Wiley InterScience (www.interscience.wiley.com). DOI 10.1002/hep.22945

Potential conflict of interest: Nothing to report.

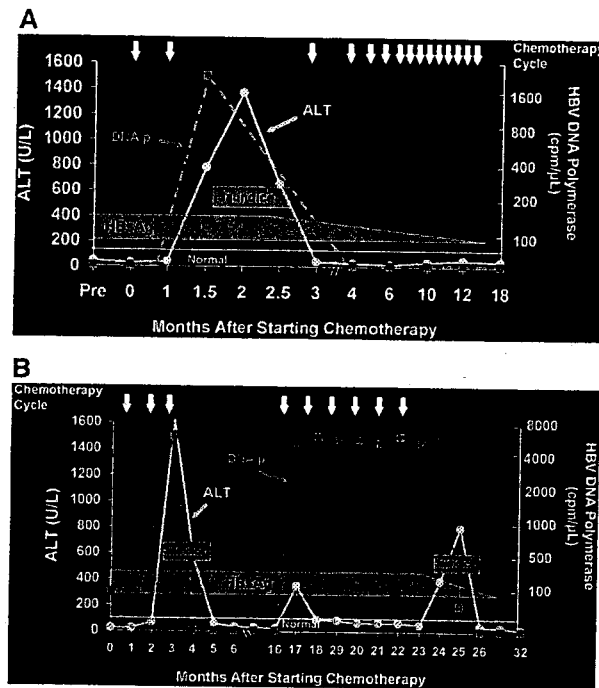


Fig. 1. (A) Reactivation of hepatitis B in an HBsAg carrier with testicular cancer undergoing cyclic chemotherapy. After the second course of chemotherapy, he presented with jaundice and marked elevations in ALT and HBV DNA polymerase activity in serum. Testing of stored serum demonstrated HBsAg without HBeAg or detectable HBV DNA before chemotherapy. The acute hepatitis eventually resolved and he tolerated further courses of chemotherapy without recurrent reactivation. In follow-up 18 months later, he was HBsAg-negative and anti-HBs positive. (B) Reactivation of hepatitis B in an HBsAg carrier with non-Hodgkin's lymphoma undergoing cyclic chemotherapy. After the third course of chemotherapy, she presented with jaundice and marked elevations in ALT and HBV DNA polymerase activity. Testing of stored serum demonstrated HBsAg without HBeAg and low levels of HBV DNA polymerase in serum before chemotherapy. The acute hepatitis eventually resolved, but she developed HBV reactivation again when chemotherapy was restarted. Prospective monitoring demonstrated the rise in HBV DNA with the first course of treatment, but only mild ALT elevations and no clinical symptoms until chemotherapy was stopped, at which point she suffered a severe bout of icteric hepatitis. Approximately 6 months later, she was found to have cleared HBsAg and tested positive for anti-HBs. Modified with permission from Hoofnagle et al.³

of liver disease (drug-induced liver disease, alcoholic liver disease) occurring in a previously stable, inactive HBV carrier. There is a need for a wider awareness about reactivation of hepatitis B, when and where it occurs and how it should be prevented or managed.

Virological and Clinical Features of HBV Reactivation

HBV reactivation occurs in many situations in which a person with mild or inactive hepatitis B is exposed to immunosuppressive agents or suffers from immune deficiency. Reactivation has been shown to occur with chemotherapy for solid cancers and leukemia¹⁻⁵ particularly when using rituximab,⁶ with immune modulation using prednisone or infliximab for autoimmune conditions;^{7,8} with progression of human immunodeficiency virus (HIV) infection;⁹ after solid organ transplantation (heart, lung, kidney);^{10,11} and, most commonly and dramatically, after bone marrow^{12,13} and liver transplantation.¹⁴

The typical course of reactivation is shown in Fig. 1, which shows the course of two hepatitis B surface antigen (HBsAg)-positive patients who received cancer chemo-

therapy in the early 1980s before the availability of antiviral therapy which might alter the course and outcome.³ HBV reactivation can be separated into three phases: (1) increase in HBV replication; (2) appearance of hepatic injury; and (3) recovery (Table 1).

Reactivation starts with the abrupt increase in viral replication that typically occurs soon after initiating immune suppression or chemotherapy. The degree of increase in viral replication is measured by the rise in HBV DNA in serum (the examples show HBV DNA polymer-

Table 1. Three Phases of HBV Reactivation

Phase	Feature	Diagnostic Markers	Comments
1	Increase in Viral Replication	HBV DNA HBeAg HBsAg	Rise of > 1 log ₁₀ IU/mL in HBeAg negative Reverse seroconversion
2	Appearance of Disease Activity	ALT Symptoms Jaundice	Rise of > 3 times baseline Indicative of more severe injury
3	Recovery	HBV DNA ALT HBsAg	Fall to baseline values Fall to baseline values May be cleared late

ase activity, an insensitive, early quantitative measure of viral replication). In patients without hepatitis B e antigen (HBeAg), this marker may reappear in the serum. The second phase of reactivation starts when immunosuppression is withdrawn or decreased and hepatocellular injury or hepatitis arises, as shown by rises in serum aminotransferase levels and, in more severe instances, symptoms and jaundice. During this phase, HBV DNA levels may start to fall. The third phase of reactivation is recovery, as the evidence of liver injury resolves and HBV markers return to baseline levels.

Nor all patients with reactivation have all three phases. In some patients, HBV DNA reappears and rises to high levels, but there is no immune reconstitution and no liver injury arises. These patients also typically do not recover completely, a pattern that is common in patients who remain immunosuppressed, such as solid organ and bone marrow transplant recipients.¹⁰⁻¹³ In other patients, the hepatitis phase is severe and can be fatal so that recovery does not occur.¹⁴ In other instances, the hepatitis phase persists and a chronic hepatitis is established, of varying severity. Finally, recovery may be marked by a return to the previous inactive state of hepatitis B or may actually result in more complete recovery. In the examples shown in Fig. 1, both patients ultimately became HBsAg-negative and developed antibody to HBsAg (anti-HBs). The examples also show that restarting chemotherapy and immune suppression does not necessarily cause recurrence of reactivation (Fig. 1A), but in some instances can (Fig. 1B).

The Frequency of HBV Reactivation

The frequency of reactivation is not well defined. In a landmark study from the 1980s, investigators from Hong Kong carefully followed 100 patients with lymphoma while undergoing cancer chemotherapy for virological, serological, and biochemical evidence of reactivation.⁴ Almost half of the 27 HBsAg-positive patients (48%) developed reactivation during or shortly after chemotherapy, compared to 0 of 22 patients with no serological markers for ongoing or previous hepatitis B. Importantly, two of 51 patients (4%) with serological evidence of resolved hepatitis B (without HBsAg, but with antibody to hepatitis B core antigen [anti-HBc] in serum) developed reactivation with reappearance of HBsAg in serum. This latter pattern is commonly referred to as "reverse seroconversion." In this initial prospective study, half of patients who developed reactivation became jaundiced, and 20% of patients with jaundice died. While the incidence of reactivation has varied in different case series, the fatality rate of HBV reactivation has been consistently greater than

10%, far higher than the fatality rate of typical acute hepatitis B and similar to fatality rates of hepatocellular drug-induced liver injury.

A recent meta-analysis of the role of prophylaxis with lamivudine in preventing reactivation of hepatitis B has provided support for these early results on the frequency of its occurrence.¹⁵ Among 13 studies enrolling 424 patients who did not receive prophylaxis, the combined rate of HBV reactivation was 50%, ranging in individual studies from 24%-88%. Subsequent studies have assessed risk factors for developing reactivation; the likelihood of HBV reactivation is higher in patients with HBeAg or HBV DNA before chemotherapy¹⁶ and with the use of corticosteroids in the chemotherapy regimen.¹⁷ Actually, the most important factor—the aggressiveness of the cancer chemotherapy or rigor and duration of immune suppression—could not be analyzed in these studies because of the homogenous populations enrolled.

The role of degree of immunosuppression in the frequency and severity of HBV reactivation is highlighted by reports of severe reactivation following more aggressive forms of chemotherapy or immune suppression such as with the use of rituximab⁸ or fludarabine¹⁸ in the therapy of lymphoma. Rituximab is a monoclonal antibody against CD20, a major cell surface marker on B cells, which effectively reduces B cell numbers and antibody levels. The rate of HBV reactivation with rituximab therapy has not been defined but appears to be high. Thus, in the 12 individual case reports of HBV reactivation associated with rituximab therapy in the literature, the mortality rate was 83%, and five cases occurred in patients who were HBsAg-negative before therapy (reverse seroconversion).^{8,18-28} In cases of reverse seroconversion, the reappearance of HBsAg and HBV DNA typically occurs late, after several cycles of chemotherapy with rituximab, and generally at a time when anti-HBs and anti-HBc have fallen to low or undetectable levels (Fig. 2).²⁶

HBV Reactivation After Immune Suppression for Nonmalignant Disease

Reactivation is not limited to patients with cancer undergoing chemotherapy (Table 2). Simple immune suppression as is given to patients with autoimmune or allergic diseases who have either HBsAg or anti-HBc in serum can also induce reappearance of HBV replication and disease activation, although at a lower rate than occurs with cancer chemotherapy.⁷ Thus, reactivation of hepatitis B is uncommon with immune suppression using azathioprine and low doses of corticosteroids, but has been reported (rarely) with long-term use of methotrexate.²⁹⁻³¹ Although rare reports of reactivation have been described in patients receiving corticosteroids alone, more

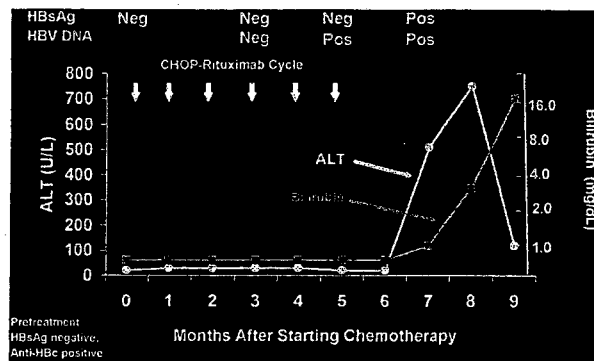


Fig. 2. Fatal reactivation of hepatitis B with reverse seroconversion in a patient with large B-cell lymphoma treated with rituximab-CHOP (cyclophosphamide, doxorubicin, vincristine, and dexamethasone). The patient was HBsAg-negative but anti-HBc-positive before therapy, becoming HBV DNA-positive during the last six cycles of chemotherapy and subsequently developing HBsAg and rising levels of ALT and bilirubin leading to acute liver failure and death. Modified from Yamagata et al.²⁸

striking examples occur after the use of potent immune suppression such as with anti-tumor necrosis factor-alpha therapies (infliximab).⁸ Thus, there have been more than a dozen published reports of severe reactivation (three being fatal) after use of infliximab for Crohn's disease, rheumatoid arthritis, or ankylosing spondylitis which has resulted in a "black box" warning.^{8,32-36} The rates of reactivation have been difficult to ascertain, because only rare patients receiving these therapies have pre-existing HBsAg or anti-HBc, and prophylaxis with nucleoside analog is now common. In a study from Spain,⁸ patients who were both HBsAg-positive and who did not receive prophylaxis with lamivudine developed severe reactivation after treatment with infliximab, whereas no patient given lamivudine prophylaxis during infliximab therapy developed reactivation.

Organ Transplantation and HBV Reactivation

Solid organ transplantation usually requires long-term moderate-to-severe immune suppression to prevent rejection and, consequently, is a setting for occurrence of HBV reactivation in susceptible patients. Before the introduction of antiviral prophylaxis, the rates of HBV reactivation after renal transplantation ranged from 50%-94%.^{10,37-39} Reactivation was frequently subclinical and resulted in chronic

Table 2. Different Causes and Forms of HBV Reactivation

Spontaneous
Progressive Immunodeficiency (HIV Infection)
Sudden Withdrawal of Antiviral Therapy
Cancer Chemotherapy
Immunosuppression for Autoimmune or Allergic Conditions
Solid Organ Transplantation (Kidney, Heart, Lung)
Liver Transplantation (Reactivation In Graft)
Bone Marrow Transplantation

hepatitis rather than acute reactivation episodes. For this reason, the frequency and consequences of HBV reactivation were often overlooked. A similarly high rate of reactivation occurs after heart transplantation.¹¹ Rates of reverse seroconversion after kidney and heart transplantation have not been well defined, but may be rising in recent years with the use of more potent antirejection regimens.¹⁰ Currently, patients evaluated for heart, lung, and kidney transplantation are routinely tested for HBsAg and anti-HBc and, if positive, considered for antiviral prophylaxis and long-term antiviral treatment.⁴⁰ At issue is the long-term benefit of this approach and whether antiviral therapy must be continued indefinitely.

Liver transplantation offers a special and somewhat confusing example of reactivation. Because the infected liver is removed at transplantation, the reappearance of HBsAg and HBV DNA afterwards in HBV-infected transplant recipients is considered reinfection rather than reactivation. Reinfection is almost universal after liver transplantation in patients who are HBsAg-positive, but can be reliably prevented by appropriate use of hepatitis B immune globulin and antiviral therapy.^{40,41} Reinfection after liver transplantation for patients with anti-HBc without HBsAg appears to be uncommon, and such patients are usually not given immunoprophylaxis or long-term therapy.⁴¹

Reactivation in the setting of liver transplantation occurs when the organ donor rather than recipient is positive for HBsAg or, more frequently, for anti-HBc. Indeed, the most dramatic examples of reverse seroconversion occur with the transplantation of a liver from a donor with anti-HBc without HBsAg into a recipient without HBV infection.^{14,42-46} Retrospective analyses indicate that approximately 70% of such transplants result in HBV infection in the recipient and almost always results in chronic infection which can be progressive and severe.¹⁴

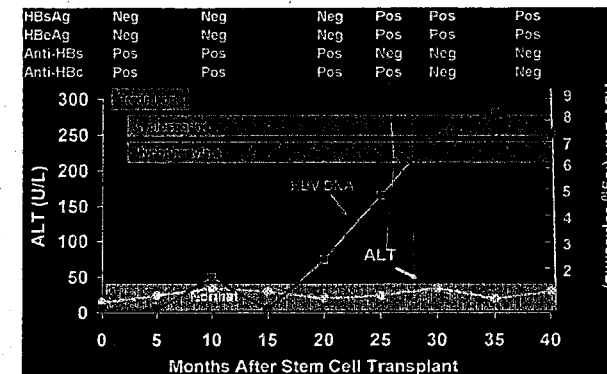


Fig. 3. Reverse seroconversion occurring 20 months after successful bone marrow transplantation for chronic myelogenous leukemia in a patient who was HBsAg-negative but anti-HBs-positive and anti-HBc-positive before transplant. Levels of anti-HBs and anti-HBc fell during 16 months after transplantation, and HBV DNA arose shortly thereafter. HBsAg was detected once HBV DNA levels rose above 1000 copies/mL. The patient required continued immunosuppression with prednisone, cyclosporine, and mycophenylate mofetil for graft-versus-host disease. Serum ALT levels remained normal. Modified from Knoll et al.¹²

The reappearance of hepatitis B in the recipient of a liver donor with serological evidence of recovery from hepatitis B (anti-HBc with or without anti-HBs in the absence of HBsAg) indicates that HBV can become latent and that virus with replicative capabilities remains in the liver in patients who have recovered from hepatitis B. Indeed, blood from such donors can be infectious for hepatitis B,⁴⁷ and persons who have recovered from acute or chronic hepatitis B have been shown to harbor HBV DNA in liver despite absence of active liver disease or presence of HBsAg or HBV DNA in serum.⁴⁸⁻⁵⁰

For these reasons, donors with anti-HBc (even without HBsAg) are not used in liver transplantation, unless they are given to patients undergoing transplantation for hepatitis B (and thus who will receive antiviral prophylaxis) or are given with informed consent to a patient who receives long-term prophylaxis with an antiviral agent.^{40,41} Reactivation can be prevented by prophylactic antiviral therapy in this situation, but the long-term efficacy and safety of this latter approach have yet to be fully documented.⁵¹⁻⁵⁵

Bone Marrow Transplantation and HBV Reactivation

Perhaps the most dramatic examples of HBV reactivation have been described in patients undergoing bone marrow transplantation. In typical allogeneic bone marrow transplantation, the recipient bone marrow is ablated using high doses of chemotherapy and then replaced by the infusion of donor marrow from someone who may or may not have immunity to hepatitis B. Thus, bone marrow transplantation represents the most extreme form of immune suppression/ablation. Reactivation of hepatitis B is almost universal among patients with HBsAg undergoing bone marrow transplantation.^{56,57} In addition, reverse seroconversion is common, although it is often not de-

tected or is misdiagnosed.^{12,13,58-60} In retrospective analyses using sensitive serological and virological markers, a high proportion of persons with anti-HBs without HBsAg in serum redeveloped HBV DNA and HBsAg after bone marrow transplantation, occurring in three of six patients (50%) in a study from Germany¹² and in seven of 14 patients (50%) in a study from Japan.¹³ Serial testing demonstrated that the bone marrow recipients gradually lost anti-HBs reactivity, with levels of antibody falling to undetectable between 1 and 3 years after transplantation. With loss of anti-HBs (and anti-HBc), HBV DNA appeared and levels increased; once HBV DNA levels rose above ~1000 copies/mL (~200 IU/mL), HBsAg typically appeared in the serum (Fig. 3). In the case series, most patients did not develop clinically apparent hepatitis, but among those with clinically apparent disease, fatalities are not infrequent. Importantly, reactivation and particularly reverse seroconversion usually occurred late, between 1 and 3 years after the bone marrow transplantation, and further follow-up may show that a higher proportion of patients would eventually become infected. Because of multiple publications of fatal instances of reverse seroconversion after bone marrow transplantation, current recommendations are for all potential marrow recipients to be tested for HBsAg, anti-HBs, and anti-HBc and patients with HBV markers should receive antiviral prophylaxis. Although this approach appears to be effective, the late development of reactivation after bone marrow transplantation suggests that long-term, if not lifelong, antiviral prophylaxis may be necessary.⁶¹⁻⁶⁶

Spontaneous Reactivation

Chronic hepatitis B is a dynamic condition, and patients with inactive infection (the inactive HBsAg carrier state) can revert spontaneously to the immune-active

phase with reappearance of high levels of HBV DNA and disease activity.⁶⁷⁻⁶⁹ Indeed, a not uncommon pattern of disease in patients with HBsAg-negative chronic hepatitis B is a relapsing course with periods of normal alanine aminotransferase (ALT) levels and no or low levels of HBV DNA followed by acute episodes of marked ALT elevations and HBV DNA detectability.⁷⁰ This pattern represents recurrent HBV reactivation and can present in a fashion resembling acute viral hepatitis^{71,72} and appears to have a high likelihood of resulting in cirrhosis.^{69,70} Spontaneous reactivation of chronic hepatitis B is often misdiagnosed,⁷³ yet this pattern of disease activity has been found to be quite responsive to antiviral therapy with nucleoside analogs which block the episodic flares of disease.⁷⁰

Reactivation of Hepatitis B in HIV-Infected Patients

The progressive immunodeficiency that accompanies chronic infection with HIV can lead to reactivation in patients with chronic HBV infection and reverse seroconversion in patients with anti-HBc without HBsAg in serum. Testing of stored serum specimens from patients with HIV infection followed in clinical research cohorts has identified several instances in which anti-HBs reactivity is gradually lost and HBsAg with HBV DNA and ALT elevations appears.⁷⁴⁻⁷⁶ Many of the antiretroviral agents used to treat HIV infection also have activity against HBV, and in several instances, patients have had sudden exacerbation of chronic hepatitis B when HIV medications are adjusted and drugs with activity against HBV (lamivudine, tenofovir, emtricitabine) are discontinued.⁷⁷ A similar severe flare in hepatitis that is potentially fatal can occur in HIV-uninfected individuals who abruptly stop lamivudine therapy.⁷⁸ For these reasons, patients with HIV infection should be tested for HBV markers and patients with HBsAg and/or anti-HBc should not be switched away from agents with anti-HBV activity.

Prevention of Reactivation

Controlled clinical trials^{79,80} and several subsequent meta-analyses^{15,81,82} have shown that prophylaxis with nucleoside analogs (most commonly lamivudine) decreases the incidence of HBV reactivation and the frequency of clinical hepatitis and death from HBV-associated liver injury in patients undergoing cancer chemotherapy. Initiating therapy once reactivation has occurred is typically done for control subjects in these trials and appears to be ineffective.

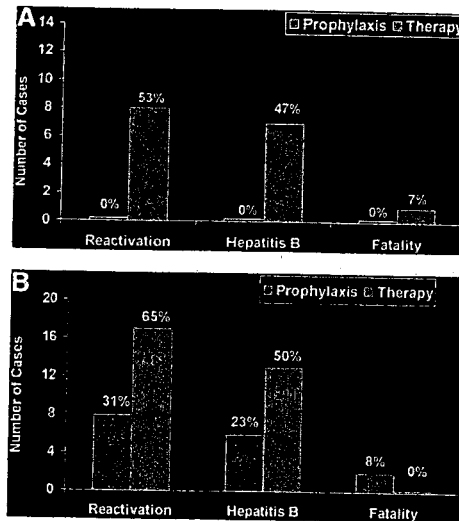


Fig. 4. Rates of HBV reactivation, hepatitis, and fatal hepatitis in two prospective, randomized controlled trials of prophylactic versus delayed (therapeutic) lamivudine in patients with malignant lymphoma undergoing cancer chemotherapy. (A) Study from Hong Kong in 30 patients.⁷⁹ (B) Study from Taiwan in 52 patients⁸⁰; numbers in the horizontal bars represent number of cases that arose during the period of prophylaxis versus number of cases that arose afterward.

There have been two prospective, randomized controlled trials of lamivudine prophylaxis against HBV reactivation in patients with HBsAg who were undergoing chemotherapy for malignant lymphoma. Both studies were conducted in Asia, one from Hong Kong⁷⁹ and one from Taiwan.⁸⁰ Both studies enrolled HBsAg-positive patients only (not those with anti-HBc without HBsAg) who were scheduled to undergo chemotherapy for previously untreated lymphoma. In the study from Hong Kong,⁷⁹ 30 patients were enrolled and randomized to receive prophylactic lamivudine (100 mg daily starting 1 week before chemotherapy and stopping 6 weeks after completion of the last cycle of chemotherapy) or lamivudine treatment only if reactivation were documented to occur. Reactivation was defined by a 10-fold rise of serum HBV DNA levels and "hepatitis" was defined by a three-fold increase in ALT levels in patients with HBV reactivation. Reactivation occurred in eight of 15 control subjects (53%) but 0 of 15 patients given lamivudine prophylactically ($P = 0.002$) (Fig. 4A). Seven of the eight instances of HBV reactivation were accompanied by hepatitis (88%), two were icteric (25%), and one was fatal (12%).

A second study was recently published from Taiwan⁸⁰ which employed a similar design, and, indeed, was discontinued early because of the results of the study from Hong Kong. In this multicenter trial, 52 HBsAg-positive patients with newly diagnosed non-Hodgkin's lymphoma were randomized to receive either prophylactic or therapeutic lamivudine. The prophylactic group received 100 mg daily starting 1 week before chemotherapy and continuing for 2 months after completion of chemotherapy. The therapeutic group received lamivudine if serum ALT levels rose during therapy. Definitions of HBV reactivation (1 log₁₀ rise in HBV DNA levels) and hepatitis (three-fold rise in ALT levels) were similar in the two studies. Among 26 patients receiving lamivudine prophylactically, only three (12%) developed HBV reactivation while on therapy compared to 14 of the 25 control patients (56%) ($P = 0.002$). Most control patients with HBV reactivation also fulfilled criteria for hepatitis (82%), and five patients developed jaundice. In contrast, the cases of reactivation in the prophylactic group were mild and were not accompanied by jaundice. Two of the patients who developed reactivation despite lamivudine therapy were found to harbor lamivudine-resistant HBV which had not been detected before therapy. Most importantly, HBV reactivation and hepatitis were also common after therapy was stopped, occurring in similar proportions of the prophylactic (19%) and the therapeutic (14%) groups (Fig. 4B). In addition, cases of reactivation occurring after prophylactic therapy tended to be clinically apparent: three patients developed jaundice and two died of liver failure.

Thus, both studies clearly demonstrated that prophylactic lamivudine decreased the rate of HBV reactivation and hepatitis; however, the larger trial from Taiwan, which had a more rigorous design and follow-up, demonstrated that HBV reactivation is not completely eliminated by prophylactic lamivudine treatment, perhaps because of development of lamivudine resistance, and that continuation of therapy for 2 months after stopping chemotherapy was not adequate to prevent delayed reactivation.

Prospective trials of antiviral prophylaxis have not been performed in other situations with high risk for HBV reactivation (bone marrow transplantation, solid organ transplantation, HIV infection, immune modulation for autoimmune conditions), but small case series with historical controls indicate that reactivation appears to be decreased, if not eliminated, if prophylaxis is provided.^{8,83-87} Given the safety and tolerability of current nucleoside analogs for hepatitis B and given that prophylaxis against reactivation of hepatitis B appears to be effective, it would seem appropriate to recommend its application widely.

Indeed, clinical guidelines from expert groups in Asia, Australia, Europe, Canada, and the United States all recommend prophylaxis against reactivation of hepatitis B in high-risk situations.⁸⁸⁻⁹¹

Conclusions and Recommendations

Reactivation of HBV is a common occurrence after immune suppression and can be clinically severe and result in death from acute liver failure or progressive liver disease and cirrhosis. HBV reactivation can be prevented in some instances by prophylactic use of antiviral agents. Nevertheless, it is difficult to make rigorous recommendations regarding the prevention and control of HBV reactivation. Issues include: which patients should be screened for evidence of hepatitis B before starting immune suppression or chemotherapy? Should screening tests include both HBsAg and anti-HBc? Which patients should be offered prophylaxis against reactivation? Which antiviral agent should be used? And for how long? Using what tests to monitor therapy for both efficacy and safety?

Recommendations regarding reactivation have been published by several academic societies⁸⁸⁻⁹⁰ and by the Centers for Disease Control and Prevention,⁹¹ but the recommendations differ and are frequently complex and require special expertise or knowledge about hepatitis B and its risk factors and serology. Based on the current literature about reactivation as well as the realization that chemotherapeutic and immunosuppressive regimens continue to evolve and have become more rigorous and aggressive with newer immunosuppressive agents and regimens, simple recommendations can be made, although not all are convincingly supported by medical evidence.

All patients who are to undergo cancer chemotherapy, marked immunosuppressive treatments or solid organ or bone marrow transplantation should be screened for evidence of ongoing or previous hepatitis B (for HBsAg and anti-HBc).

Persons found to be HBsAg-positive should be evaluated for indications for therapy of hepatitis B and, if found to warrant treatment, started on appropriate therapy before starting cancer chemotherapy or immune suppression. Such therapy should continue for the duration of chemotherapy and for as long as dictated by the chronic hepatitis B.

Persons found to have the inactive HBsAg carrier state or immune-tolerant chronic hepatitis B should receive antiviral prophylaxis before starting chemotherapy or immune suppression.

Persons found to have anti-HBc without HBsAg in serum should be considered for antiviral prophylaxis if they are scheduled for organ or bone marrow transplan-

tation or if aggressive or prolonged chemotherapy or immune suppression is planned.

Prophylaxis against HBV reactivation should continue for at least 6 months after stopping chemotherapy. In situations in which immune suppression is continued for the long term, long-term prophylaxis should be considered.

Although lamivudine or adefovir may be adequate for short-term prophylaxis, antiviral nucleoside analog with a higher barrier to resistance should be considered for patients in whom long-term prophylaxis is likely, particularly if high levels of HBV DNA are present before immune suppressive therapy.

Needs for Future Research

The complexity of reactivation of hepatitis B and the many issues surrounding its management call for prospective studies of its incidence, pathogenesis, treatment, and prevention. At present, recommendations have to be based on our understanding of reactivation, uncontrolled observations, and limited studies of its prevention. Because the oral nucleoside analogs active against hepatitis B are relatively potent and are well tolerated, prevention is easy to recommend. More difficult is to decide when to stop therapy and how to monitor patients before or during prophylaxis. Although future controlled studies of prophylaxis versus no prophylaxis are not warranted, controlled trials of different approaches to prophylaxis are reasonable and would provide valuable information. Thus, prospective clinical trials might compare the efficacy of lamivudine versus entecavir or tenofovir, or evaluate discontinuation of prophylaxis at 2 versus 12 months after stopping chemotherapy. Studies of nonliver organs from donors with anti-HBc without HBsAg might be developed that compared limited, short-term prophylaxis to continued antiviral therapy. These studies should include careful virological analyses and ancillary studies directed at elucidating the nature of HBV latency, factors that lead to an increase in HBV replication and liver cell injury, and features of the innate and adaptive immune system that lead to immune clearance of HBV after acute reactivation.

References

- Galbraith RM, Eddleston AL, Williams R, Zuckerman AJ, Bagshawe KD. Fulminant hepatic failure in leukemia and choriocarcinoma related to withdrawal of cytotoxic drug therapy. *Lancet* 1975;2:528-530.
- Wands JR, Chura CM, Roll FJ, Maddrey WC. Serial studies of hepatitis-associated antigen and antibody in patients receiving antitumor chemotherapy for myelo-proliferative and lymphoproliferative disorders. *Gastroenterology* 1975;68:105-112.
- Hoofnagle JH, Dusheiko GM, Schaffer DF, Jones EA, Micetich KC, Young RC, et al. Reactivation of chronic hepatitis B virus infection by cancer chemotherapy. *Ann Intern Med* 1982;96:447-449.

- Lok ASF, Liang RHS, Chiu EKW, Wong K-L, Chan T-K, Todd D. Reactivation of hepatitis B virus replication in patients receiving cytotoxic therapy. Report of a prospective study. *Gastroenterology* 1991;100:182-188.
- Yeo W, Chan PKS, Zhong S, Ho WM, Steinberg JL, Tam JS, et al. Frequency of hepatitis B virus reactivation in cancer patients undergoing cytotoxic chemotherapy: a prospective study of 626 patients with identification of risk factors. *J Med Virol* 2000;62:299-307.
- Dervizi I, Hober D, Morel P. Acute hepatitis B in a patient with antibodies to hepatitis B surface antigen who was receiving rituximab. *N Engl J Med* 2001;344:68-69.
- Rostoker G, Rosenbaum J, Ben Maadi A, Nedelec G, Deforge L, Vidaud M, et al. Reactivation of hepatitis B virus by corticosteroids in a case of idiopathic nephritic syndrome. *Nephron* 1990;56:224.
- Esteve M, Saro C, Gonzalez-Huix F, Suarez F, Forne M, Viver JM. Chronic hepatitis B reactivation following infliximab therapy in Crohn's disease patients: need for primary prophylaxis. *Gut* 2004;53:1363-1365.
- Waite J, Gilson RJC, Weller IAVD, Lacey CHN, Hambling MH, Hawkins A, et al. Hepatitis B virus reactivation or reinfection associated with HIV-1 infection. *AIDS* 1988;2:443-448.
- Marcellin P, Giotra E, Marinou-Peignoux M, Liorat M-A, Jaeger M-L, Wolf P, et al. Redeposition of hepatitis B surface antigen after renal transplantation. *Gastroenterology* 1991;100:1432-1434.
- Ko W-J, Chou N-K, Hsu R-B, Chen Y-S, Wang S-S, Chu S-H, et al. Hepatitis B virus infection in heart transplant recipients in a hepatitis B endemic area. *J Heart Lung Transplant* 2001;10:865-875.
- Knoll A, Boehm S, Hahn J, Holler E, Jilg W. Reactivation of resolved hepatitis B virus infection after allogeneic haematopoietic stem cell transplantation. *Bone Marrow Transplant* 2004;33:925-929.
- Onozawa M, Hashino S, Izumiya K, Kahata K, Chuma M, Mori A, et al. Progressive disappearance of anti-hepatitis B surface antigen antibody and reverse seroconversion after allogeneic hematopoietic stem cell transplantation in patients with previous hepatitis B virus infection. *Transplantation* 2005;79:616-619.
- Dickson RC, Everhart JE, Lake JR, Wei Y, Seaberg EC, Wiesner RH, et al. NIDDK Liver Transplantation Database. Transmission of hepatitis B by transplantation of livers from donors positive for antibody to hepatitis B core antigen. *Gastroenterology* 1997;113:1668-1674.
- Loomba R, Rowley A, Wesley R, Liang TJ, Hoofnagle JH, Pucino F, et al. Systematic review: the effect of preventive lamivudine on hepatitis B reactivation during chemotherapy. *Ann Intern Med* 2008;148:519-528.
- Yeo W, Zee B, Zhong S, Chan PKS, Wong W-L, Ho WM, et al. Comprehensive analysis of risk factors associated with hepatitis B virus (HBV) reactivation in cancer patients undergoing cytotoxic chemotherapy. *Br J Cancer* 2004;90:1306-1311.
- Cheng A-L, Hsiung C-A, Su J-J, Chen P-J, Chang M-C, Tzao C-J, et al. Lymphoma Committee of Taiwan Cooperative Oncology Group (TCOG). Steroid free chemotherapy decreases risk of hepatitis B virus (HBV) reactivation in HBV-carriers with lymphoma. *HEPATOLOGY* 2003;37:1320-1328.
- Ng HJ, Lim LC. Fulminant hepatitis B virus reactivation with concomitant listeriosis after fludarabine and rituximab therapy: case report. *Ann Hematol* 2001;80:549-552.
- Skrabs C, Muller C, Agis H, Mannhalter C, Jager U. Treatment of HBV-carrying lymphoma patients with rituximab and CHOP: a diagnostic and therapeutic challenge. *Leukemia* 2002;16:1884-1886.
- Westhoff TH, Jochimsen F, Schmiedel A, Stoffler-Meilicke M, Schaefer JH, Zidek W, et al. Fatal hepatitis B virus reactivation by an escape mutant following rituximab therapy. *Blood* 2003;102:1930.
- Tsutsumi Y, Kawamura T, Saitoh S, Yamada M, Obara S, Miura T, et al. Hepatitis B virus reactivation in a case of non-Hodgkin's lymphoma treated with chemotherapy and rituximab: necessity of prophylaxis for hepatitis B virus reactivation in rituximab therapy. *Leuk Lymphoma* 2004;45:627-629.
- Sarrecchia C, Cappelli A, Aiello P. HBV reactivation with fatal fulminant hepatitis during rituximab treatment in a subject negative for HBsAg and positive for HBsAb and HBeAb. *J Infect Chemother* 2005;11:189-191.
- Nicola P, Del Principe MI, Maurillo L, Venditti A, Buccisano F, Piccioni D, et al. Fulminant B hepatitis in a surface antigen-negative patient with B-cell chronic lymphocytic leukaemia after rituximab therapy. *Leukemia* 2005;19:1840-1841.
- Law JK, Ho JK, Hoskins PJ, Erb S, Steinbrecher UP, Yoshida EM. Fatal reactivation of hepatitis B post-chemotherapy for lymphoma in a hepatitis B surface antigen-negative, hepatitis B core antibody-positive patient: potential implications for future prophylaxis recommendations. *Leuk Lymphoma* 2005;46:1085-1089.
- Seta T, Hiasa Y, Michitaka K, Konishi I, Masuura K, Tokumoto Y, et al. Anti-HBs-positive liver failure due to hepatitis B virus reactivation induced by rituximab. *Intern Med* 2006;45:721-724.
- Yamagata M, Murohisa T, Tsuchida K, Okamoto Y, Tsunoda S, Nakamura M, et al. Fulminant B hepatitis in a surface antigen and hepatitis B DNA-negative patient with diffuse large B-cell lymphoma after CHOP chemotherapy plus rituximab. *Leuk Lymphoma* 2007;48:431-433.
- Hernandez JA, Diloy D, Salat D, del Rio N, Martinez S, Castellvi JM. Fulminant hepatitis subsequent to reactivation of precore mutant hepatitis B virus in a patient with lymphoma treated with chemotherapy and rituximab. *Haematologica* 2007;88:394-395.
- Dillon R, Hirschfield GM, Allison ME, Rege KP. Fatal reactivation of hepatitis B after chemotherapy for lymphoma. *BMJ* 2008;337:e423.
- Flowers MA, Heathcote J, Wanless I, Sherman M, Reynolds WJ, Cameron RG, et al. Fulminant hepatitis as a consequence of reactivation of hepatitis B virus infection after discontinuation of low-dose methotrexate therapy. *Ann Intern Med* 1990;112:381-382.
- Mok MY, Ng WL, Yuen MF, Wong RW, Lau CS. Safety of disease-modifying anti-rheumatic agents in rheumatoid arthritis patients with chronic viral hepatitis. *Clin Exp Rheumatol* 2000;18:363-368.
- Ito S, Nakazono K, Murasawa A, Mita Y, Hata K, Saito N, et al. Development of fulminant hepatitis B (precore variant mutant type) after the discontinuation of low-dose methotrexate therapy in a rheumatoid arthritis patient. *Arthritis Rheum* 2001;44:339-342.
- Michel M, Dvourek C, Hecode C, Cherqui D. Fulminant hepatitis after infliximab in a patient with hepatitis B virus treated for an adult-onset Still's disease. *J Rheumatol* 2003;30:1624-1625.
- Ostuni P, Botzios C, Punzi L, Sfriso P, Todesco S. Hepatitis B reactivation in a chronic hepatitis B surface antigen carrier with rheumatoid arthritis treated with infliximab and low dose methotrexate. *Ann Rheum Dis* 2003;62:686-687.
- del Valle Garcia-Sanchez M, Gomez-Camacho F, Poyato-Gonzalez A, Iglesias-Flotes EM, de Dios-Vega JF, Sanchez-Zapatero R. Infliximab therapy in a patient with Crohn's disease and chronic hepatitis B virus infection. *Inflamm Bowel Dis* 2004;10:701-702.
- Ueno Y, Tanaka S, Shimamoto M, Miyakawa Y, Hiyama T, Ito M, et al. Infliximab therapy for Crohn's disease in a patient with chronic hepatitis B. *Dig Dis Sci* 2005;50:163-166.
- Wendling D, Auge B, Betting D, Lohse A, Le Huede G, Bresson-Hadni S, et al. Reactivation of a latent precore mutant hepatitis B virus related chronic hepatitis during infliximab treatment for severe spondyloarthropathy. *Ann Rheum Dis* 2005;64:788-789.
- Dusheiko G, Song E, Bowyer S, Whitcut M, Maier G, Meyers A, et al. Natural history of hepatitis B virus infection in renal transplant recipients - a fifteen year follow-up. *HEPATOLOGY* 1983;3:330-336.
- Degos F, Lugassy C, Degott C, Debure A, Carnot F, Thiers V, et al. Hepatitis B virus and hepatitis B-related viral infection in renal transplant recipients. A prospective study of 90 patients. *Gastroenterology* 1988;94:151-156.
- Park SK, Yang WS, Lee YS, Jung HH, Chang JW, Choi HJ, et al. Outcome of renal transplantation in hepatitis B surface antigen-positive patients after introduction of lamivudine. *Nephrol Dial Transplant* 2001;16:2222-2228.
- Terrault N. Management of hepatitis B virus infection in liver transplant recipients: prospects and challenges. *Clin Transplant* 2000;14(Suppl. 2):39-43.
- Markowitz JS, Martin P, Conrad AJ, Markmann JF, Seu P, Yersiz H, et al. Prophylaxis against hepatitis B recurrence following liver transplantation using combination of lamivudine and hepatitis B immune globulin. *HEPATOLOGY* 1998;28:585-589.
- Wachs ME, Amend WJ, Ascher NL, Bretan PN, Emond J, Lake JR, et al. The risk of transmission of hepatitis B from HBsAg (-), HBeAb (+), HBIGM(-) organ donors. *Transplantation* 1995;59:230-234.
- Dodson SF, Issa S, Araya V, Gayowski T, Antonio P, Bijan E, et al. Ineffectivity of hepatic allografts with antibodies to hepatitis B virus. *Transplantation* 1997;64:1582-1584.
- Prieto M, Gomez MD, Berenguer M, Cordoba J, Rayon JM, Pastor M, et al. De novo hepatitis B after liver transplantation from hepatitis B core antibody-positive donors in an area with high prevalence of anti-HBe positivity in the donor population. *Liver Transpl* 2001;7:51-58.
- Uemoto S, Sugiyama K, Marusawa H, Inomata Y, Asonuma K, Egawa H, et al. Transmission of hepatitis B virus from hepatitis B core antibody-positive donors in living related liver transplants. *Transplantation* 1998;65:494-499.
- Rokuhara A, Tanaka E, Yagi S, Mizokami M, Hashikura Y, Kawasaki S, et al. De novo infection of hepatitis B virus in patients with orthotopic liver transplantation: analysis by determining complete sequence of the genome. *J Med Virol* 2000;62:471-478.
- Hoofnagle JH, Seeff LB, Bales ZB, Zimmerman HJ. Type B hepatitis after transplantation with blood containing antibody to hepatitis B core antigen. *N Engl J Med* 1978;298:1379-1383.
- Yuki N, Nagaoka T, Yamashiro M, Mochizuki K, Kaneko A, Yamamoto K, et al. Long-term histologic and virologic outcomes of acute self-limited hepatitis B. *HEPATOLOGY* 2003;37:1172-1179.
- Marusawa H, Uemoto S, Hijikata M, Ueda Y, Tanaka K, Shimotohno K, et al. Latent hepatitis B virus infection in healthy individuals with antibodies to hepatitis B core antigen. *HEPATOLOGY* 2000;31:488-495.
- Fong TL, Di Bisceglie AM, Gerber MA, Waggoner JG, Hoofnagle JH. Persistence of hepatitis B virus DNA in the liver after loss of HBsAg in chronic hepatitis B. *HEPATOLOGY* 1993;18:1313-1318.
- Dodson SF, Bonham CA, Geller DA, Cacciarielli TV, Rakela J, Fung JJ. Prevention of de novo hepatitis B infection in recipients of hepatic allografts from anti-HBe positive donors. *Transplantation* 1999;68:1058-1061.
- Yu AS, Vierling JM, Colquhoun SD, Arnaout WS, Chan C-K, Khafafshar E, et al. Transmission of hepatitis B infection from hepatitis B core antibody-positive liver allografts is prevented by lamivudine therapy. *Liver Transpl* 2001;7:513-517.
- Castells L, Vargas V, Rodriguez-Frias F, Allende H, Jardi R, Margarit C, et al. Clinical impact and efficacy of lamivudine therapy in de novo hepatitis B infection after liver transplantation. *Liver Transpl* 2002;8:892-900.
- Holt D, Thomas R, Van Thiel D, Brems JJ. Use of hepatitis B core antibody-positive donors in orthotopic liver transplantation. *Arch Surg* 2002;137:572-576.
- Manzarbeitia C, Reich DJ, Ortiz JA, Rothstein KD, Araya VR, Munoz SJ. Safe use of livers from donors with positive hepatitis B core antibody. *Liver Transpl* 2002;8:556-561.
- Lau GKK, Liang R, Chiu EKW, Lee CK, Lam SK. Hepatic events after bone marrow transplantation in patients with hepatitis B infection: a case controlled study. *Bone Marrow Transplant* 1997;19:795-799.
- Martin BA, Rowe JM, Bouides PA, DiPersio JF. Hepatitis B reactivation following allogeneic bone marrow transplantation: case report and review of the literature. *Bone Marrow Transplant* 1995;15:145-148.
- Webster A, Brenner MK, Prentice HG, Griffiths PD. Fatal hepatitis B reactivation after autologous bone marrow transplantation. *Bone Marrow Transplant* 1989;4:207-208.
- Fan FS, Tzeng CH, Yeh HM, Chen PM. Reverse seroconversion of hepatitis B virus infectious status after allogeneic bone marrow transplantation from a carrier donor. *Bone Marrow Transplant* 1992;10:189-191.
- Dhedine N, Douvin C, Kuentz M, Saint Marc MF, Reman O, Rieux C, et al. Reverse seroconversion of hepatitis B after allogeneic bone marrow transplantation. *Transplantation* 1998;66:616-619.
- Myers RP, Swain MG, Urbanski SJ, Lee SS. Reactivation of hepatitis B e antigen-negative chronic hepatitis B in a bone marrow transplant recipient following lamivudine withdrawal. *Can J Gastroenterol* 2001;15:599-603.